

The Insignia System of Customized Orthodontics

ANTONIO GRACCO, DDS
STEPHEN TRACEY, DDS, MS

While technological innovations in photography, scanning, and radiology have greatly improved orthodontic diagnostic procedures,¹⁻⁵ computerized systems that design orthodontic appliances for individual patients represent a more recent breakthrough.⁶⁻¹¹ Such systems not only shorten treatment time, making cases more predictable and less labor-intensive,¹²⁻¹⁴ but allow doctors and patients to preview virtual results before treatment begins, thus facilitating communication, understanding, and cooperation.

A customized appliance system uses digital models of the patient's arches to simulate the optimal position of each dental element and the ideal final occlusion.⁶⁻¹¹ Once the desired virtual result is achieved, the personalized archwires, brackets, and indirect-bonding transfer jigs are produced. This article describes the Insignia* system, an advanced, computerized orthodontic technology used to design and fabricate personalized appliances.

System Design

As in other computerized treatment systems, Insignia treatment begins with precise polyvinyl siloxane (PVS) impressions, extremely accurate computed-tomographic (CT) scans of the impressions, digital modeling of the dental arches, and a virtual setup for ideal archform and occlusion. The impression scanning, digital modeling, and initial setup are performed by technicians at Ormco. The clinician then makes adjustments to the suggested treatment plan as desired, using Insignia's Approver** software to refine the:

- Torque, tip, in/out, intrusion, and extrusion of each tooth (Fig. 1A).
- Archform, within the patient-specific biological limits set by the osseous structure.
- Smile arc.
- Dental contacts in the final centric occlusion

(Fig. 1B).

Unlike computerized methods that simply modify the thickness of the bracket adhesive, the Insignia system reverse-engineers the brackets themselves to the correct specifications in one of two ways, depending on the type of brackets selected by the orthodontist. Insignia metal twin brackets are individualized by precision-cutting the slots in the milled-in faces. Insignia SL brackets (Fig. 1C), a customized version of the Damon Q* self-ligating model, are created by varying the thicknesses and angulations of the metallic bases. If the patient requests the use of esthetic brackets such as Inspire ICE* or Damon Clear* in the upper anterior region, a compromise customization can be achieved by matching the prescriptions of stock brackets as closely as possible to the Insignia virtual prescriptions and compensating for any differences with adjustments to the positioning jigs and custom-formed archwires.

One important feature recently added to the Insignia system is called "Overcorrection". This program tracks the three-dimensional movements of the center of resistance of the roots and the center of the bracket slot for each tooth, then calculates the tooth's direction of rotation with respect to 3rd-order constraints. Most clinicians use archwires that are undersized relative to the slot, resulting in about 10° of play. The Overcorrection software compares T1 and T2 positions to orient the slot at an angle that eliminates the archwire play, so that the tooth is driven all the way to its final position.

Another unique feature of the Insignia system is its customization of archform, based on skeletal mapping of the mandibular bone's cortical limits at the level of the center of resistance of the

*Registered trademark of Ormco, Orange, CA; www.ormco.com.

**Trademark of Ormco, Orange, CA; www.ormco.com.

Dr. Gracco is an Adjunct Professor and Dr. Tracey is a Visiting Professor, Department of Orthodontics, University of Ferrara, Via Montebello 31, 44100 Ferrara, Italy. Dr. Tracey is also in the private practice of orthodontics in Upland, CA. He is a consultant to Ormco Corporation and assisted in the development and clinical testing of the Insignia system. E-mail Dr. Gracco at antoniogracco@gmail.com.



Dr. Gracco



Dr. Tracey

teeth (Fig. 1D). Insignia archwires are not pre-formed, but individually designed to maintain the teeth in trabecular bone as much as possible. Of all the parameters in patient-specific orthodontic treatment design, the form and shape of the dental arches are by far the most variable. Skeletal mapping solves this problem. By accounting for slot play and keeping the teeth in cancellous bone, Insignia also speeds up treatment.¹⁵

The system allows 1st-order compensation bends to be made in all types of metal wires, including copper nickel titanium, nickel titanium,

stainless steel, and titanium molybdenum (Fig. 2A). Bracket-transfer jigs are precisely milled from a high-tech, spongy material to fit the occlusal surfaces of the teeth, making bracket positioning accurate and reliable (Fig. 2B). The jigs are constructed so that three-quarters of the bracket-pad edges are visible during bonding, thus facilitating removal of excess composite material before polymerization (Fig. 2C). Should a bond failure occur during treatment, the jigs can be separated and reused to reposition and rebond individual brackets.

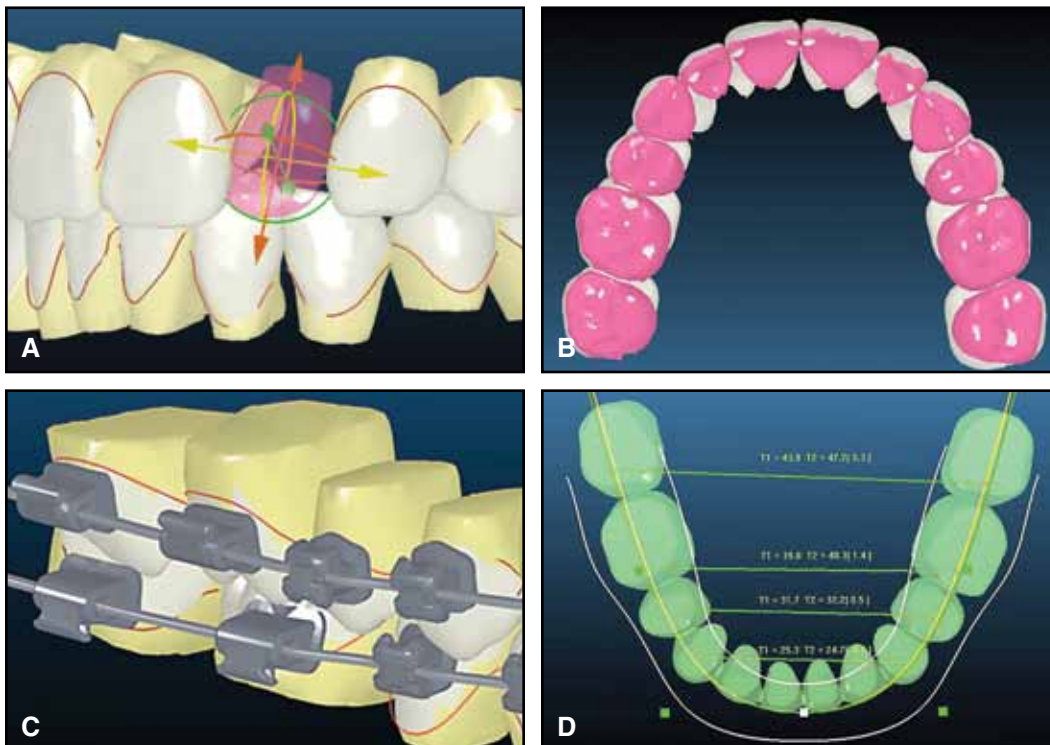


Fig. 1 A. Insignia digital setup; virtual compass tool shown on lateral incisor changes tooth position in three dimensions. B. Dental contacts in final centric occlusion (white areas). C. Customized Damon Q* brackets and torque-in-base molar tubes. D. Analysis of mandibular bone.

Two adolescent patients treated with Insignia customized appliances are shown here.

Case 1

A 16-year-old female presented with a Class II malocclusion, moderate crowding of the lower arch, and severe crowding of the upper arch, which had completely blocked out the upper right lateral incisor (Fig. 3). She had a posterior crossbite on

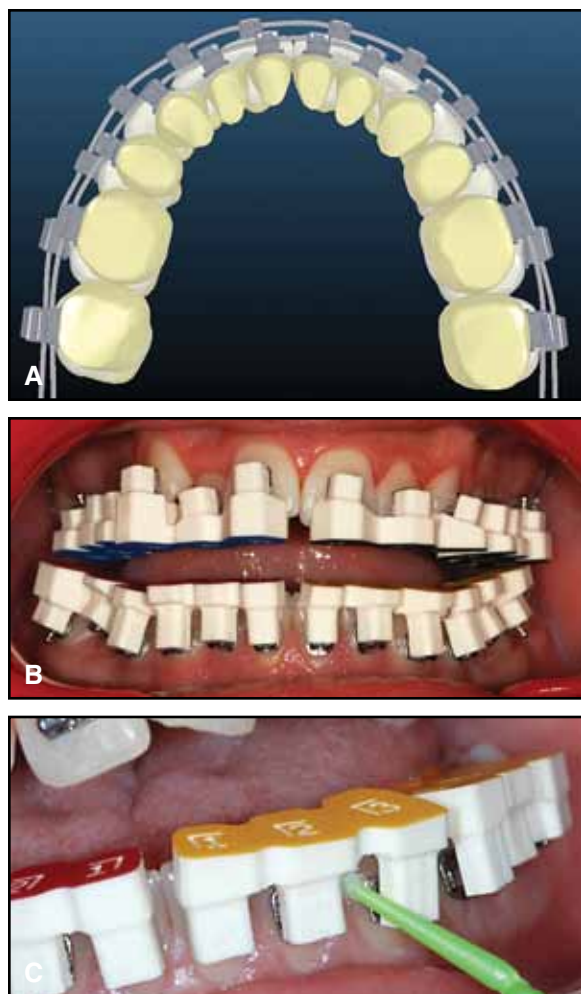


Fig. 2 A. Customized archwires with 1st-order compensation bends in upper and lower arches. B. Insignia bonding jigs placed on groups of teeth. C. Microbrush*** used to remove excess composite before light-curing.

the left side, and her maxillary midline was deviated 3mm to the right.

Treatment simulation called for opening the right lateral incisor space and correcting the malocclusion with Class II elastics. Because the gingival margins of the upper central incisors were uneven, periodontal probing was performed. We proposed gingival alignment followed by recontouring of the right central incisor edge with composite or a veneer, but the patient chose to accept the gingival-margin irregularity and simply have the incisal edges aligned.

Customized twin brackets were bonded (fully customizable self-ligating brackets were not yet available) and .014" Damon Copper Ni-Ti* wires were placed, with a nickel titanium open-coil spring between the upper right central incisor and right canine to open space for the blocked-out lateral incisor (Fig. 4A). Small amounts of composite were added to the distocclusal surfaces of the upper first molars to open the bite slightly and allow the lateral incisor to move anteriorly without obstruction. Seven months later, the lateral incisor had moved completely into the arch and was engaged to an .014" x .025" Copper Ni-Ti wire (Fig. 4B). Treatment progressed with customized .018" x .025" Copper Ni-Ti, .019" x .025" stainless steel, and .017" x .025" TMA** wires. Because the Overcorrection software feature had yet to be introduced, negative torque was applied manually to the right lateral incisor during the finishing phase to correct the root position and improve the appearance of the gingival margin (Fig. 5).

Treatment was completed in 13 visits over 20 months (Fig. 6). No bonds failed, no bracket repositioning was required, and only the single manual torquing bend was needed.

Case 2

This 15-year-old female had a Class II end-on molar relationship on the left side, a narrow

*Registered trademark of Ormco, Orange, CA; www.ormco.com.

**Trademark of Ormco, Orange, CA; www.ormco.com.

***Registered trademark of Microbrush International, Grafton, WI; www.microbrush.com.

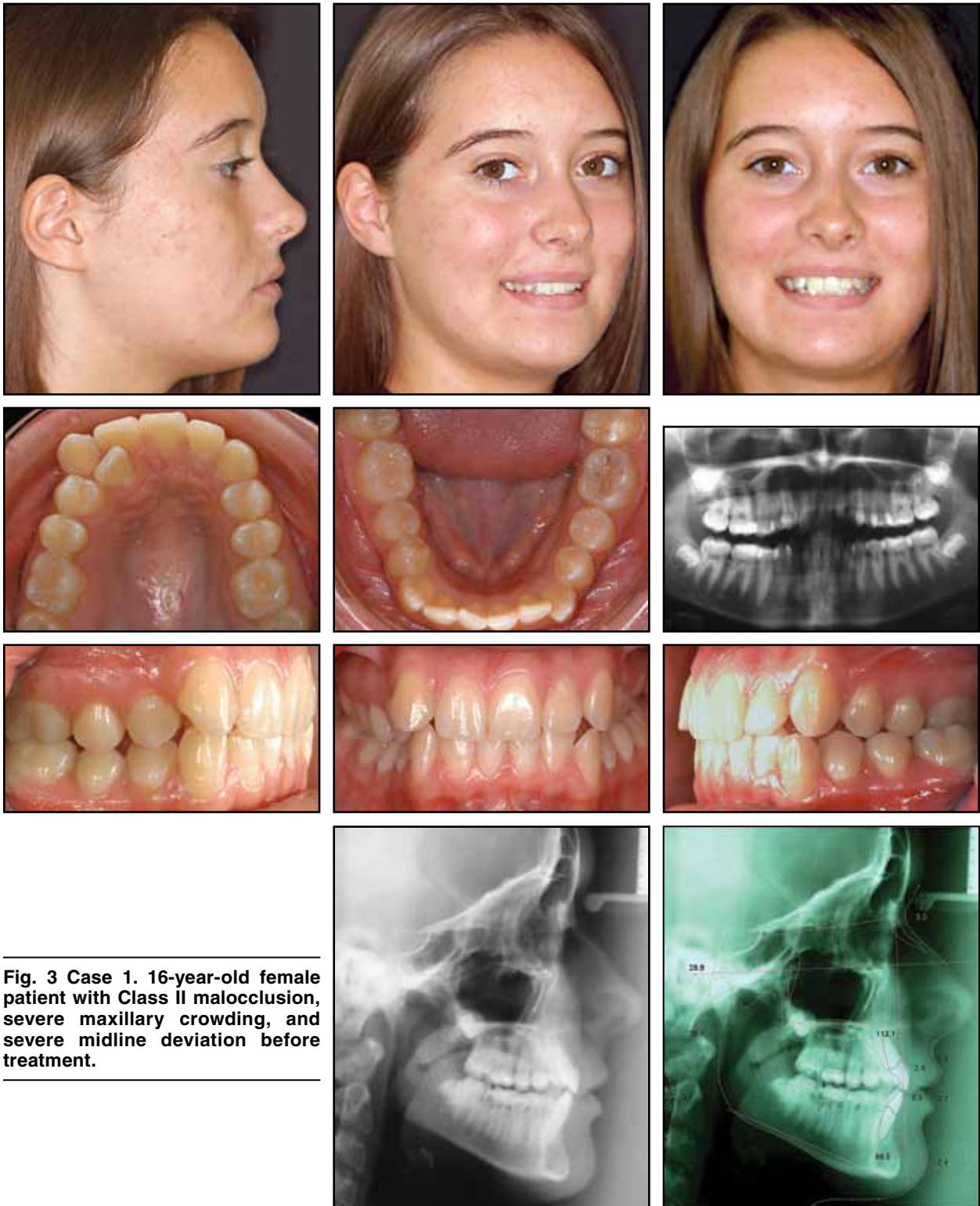


Fig. 3 Case 1. 16-year-old female patient with Class II malocclusion, severe maxillary crowding, and severe midline deviation before treatment.

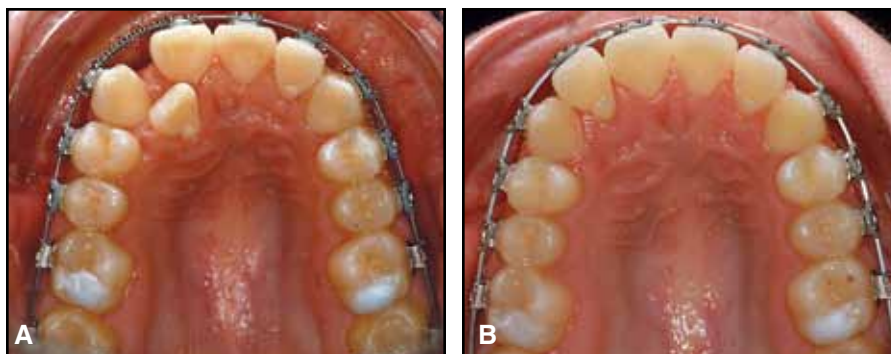


Fig. 4 Case 1. A. After four months of treatment with .014" Damon Copper Ni-Ti* archwire and nickel titanium open-coil spring between right central incisor and right canine, with composite placed on distocclusal surfaces of upper first molars for bite opening. **B.** Seven months later, .014" x .025" Copper Ni-Ti archwire in place, with upper right lateral incisor engaged, but still requiring buccal root torque.

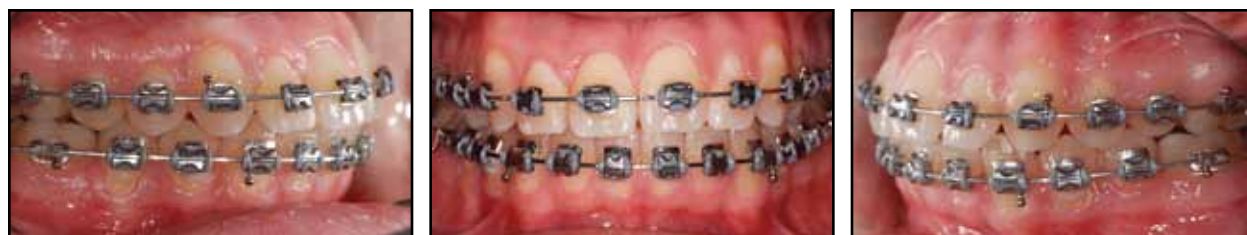

Fig. 5 Case 1. Seven months later, .019" x .025" stainless steel archwire in place, with slight negative torque added in upper right lateral incisor region.

palate, and anterior and left lateral open bites due to a tongue-thrust habit (Fig. 7).

The Insignia treatment plan was designed with customized archwires, bracket positioning, and molar-tube slot milling (Fig. 8). We chose standard Damon 3MX* brackets over fully customizable twin brackets because of our preference for the low-friction characteristics of passive self-ligating brackets over precise 3D control of the teeth in this case. Fully customizable Insignia SL brackets were not available at the time.

After two months of leveling and alignment using .014" and .014" x .025" Copper Ni-Ti archwires, Kobayashi hooks were added to the upper and lower left canines and the lower left first premolar, and triangular elastics were prescribed for

initial vertical correction of the open bite (Fig. 9A). Two months later, .018" x .025" Copper Ni-Ti archwires were inserted, and triangular elastics were then worn from the upper left canine to the lower left first premolar and first molar to apply horizontal and vertical forces for correction of the open bite and the Class II malocclusion (Fig. 9B). Three months later, .019" x .025" stainless steel archwires and bilateral triangular elastics were placed to close the bite. Finishing was initiated after another two months, using an .019" x .025" stainless steel wire in the lower arch and an .019" x .025" TMA wire in the upper (Fig. 9C). During this phase, the patient wore a Class II elastic on the left side and an anterior box elastic at night to complete the bite closure.

Treatment required 10 visits over 15 months (Fig. 10). No brackets failed, and no bracket repositioning or wire bending was required.

*Registered trademark of Ormco, Orange, CA; www.ormco.com.

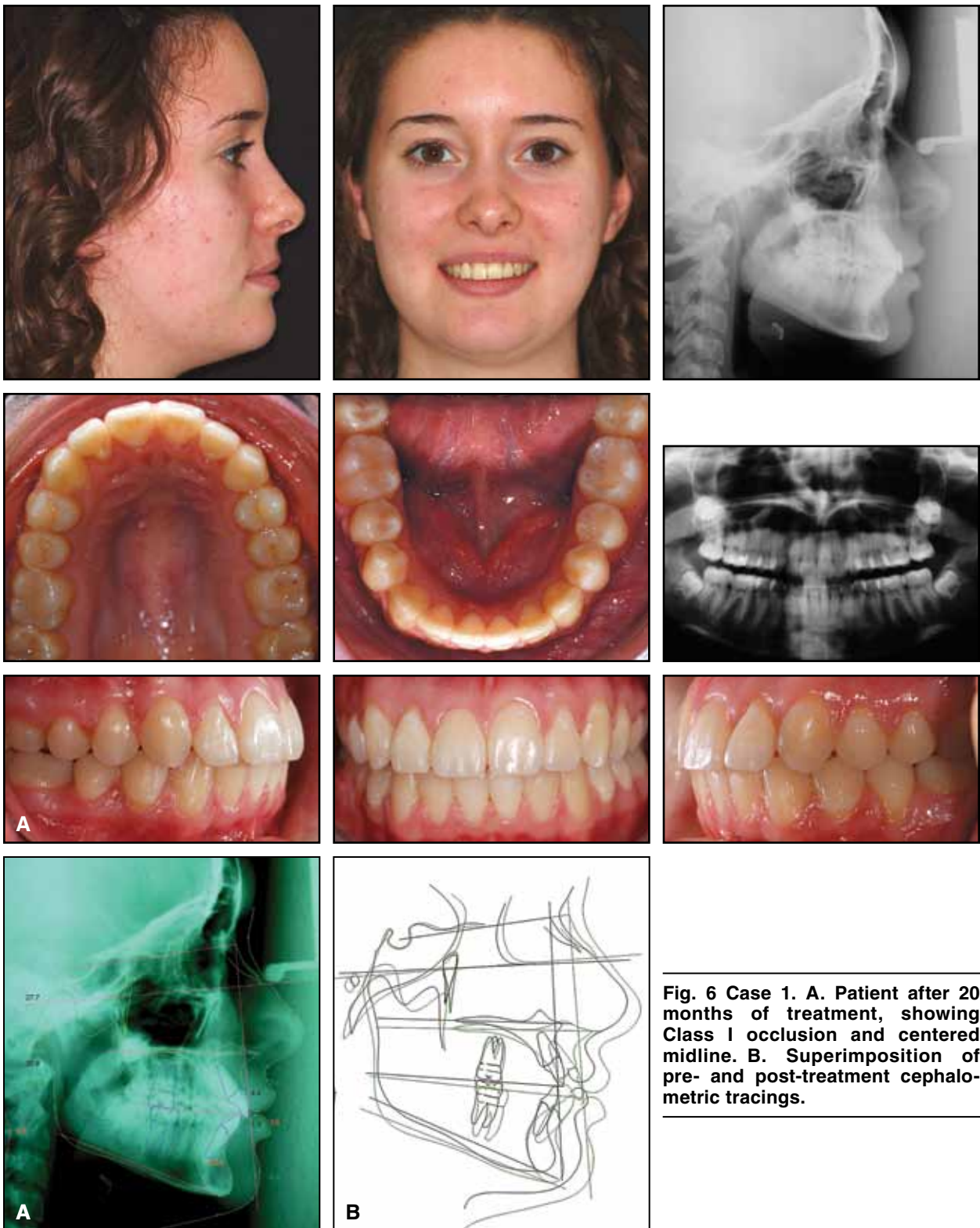


Fig. 6 Case 1. A. Patient after 20 months of treatment, showing Class I occlusion and centered midline. B. Superimposition of pre- and post-treatment cephalometric tracings.

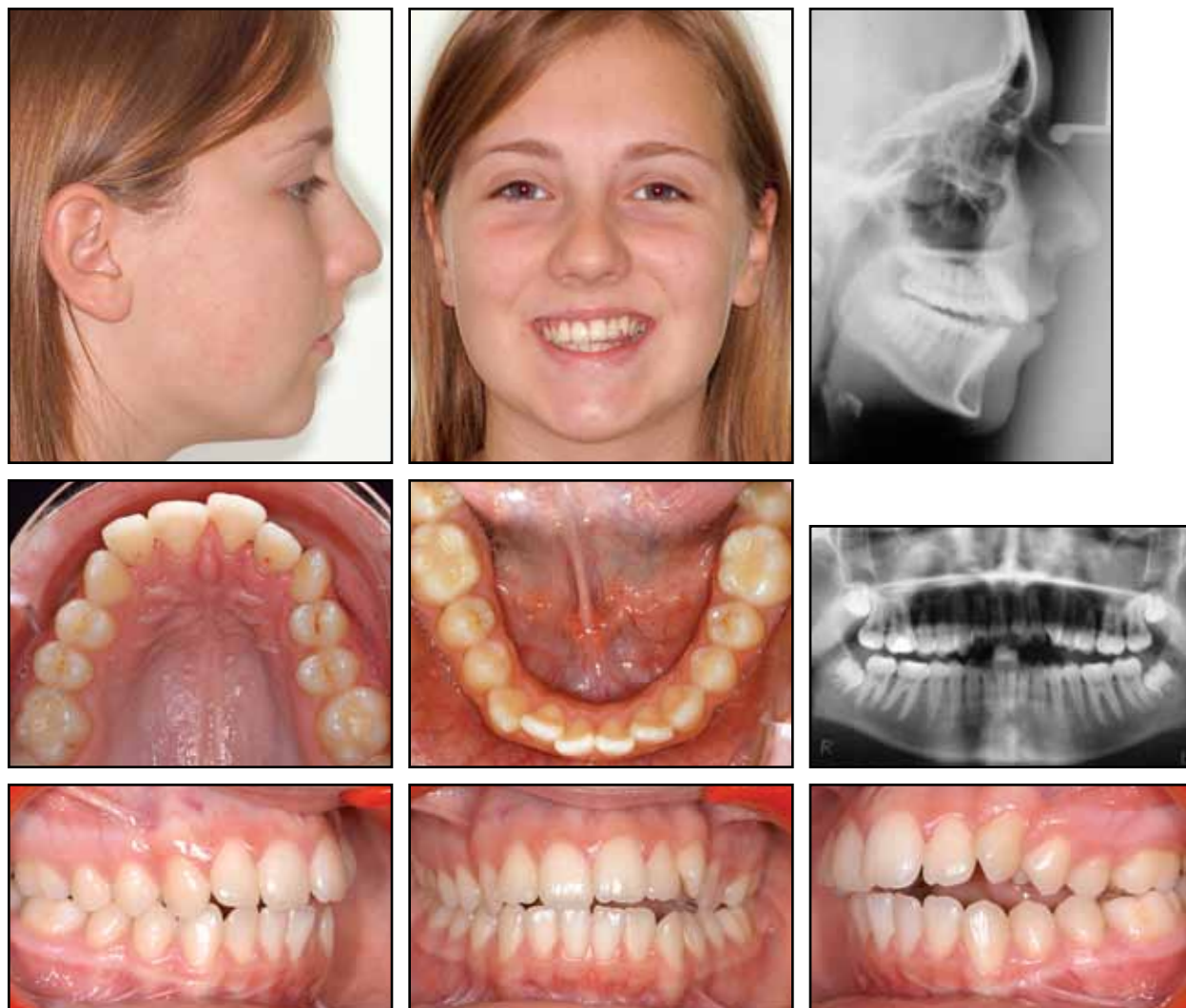
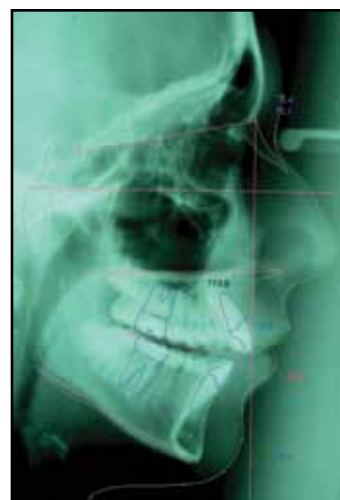

Fig. 7 Case 2. 15-year-old female patient with Class II malocclusion on left side and open bite due to tongue-thrust habit before treatment.



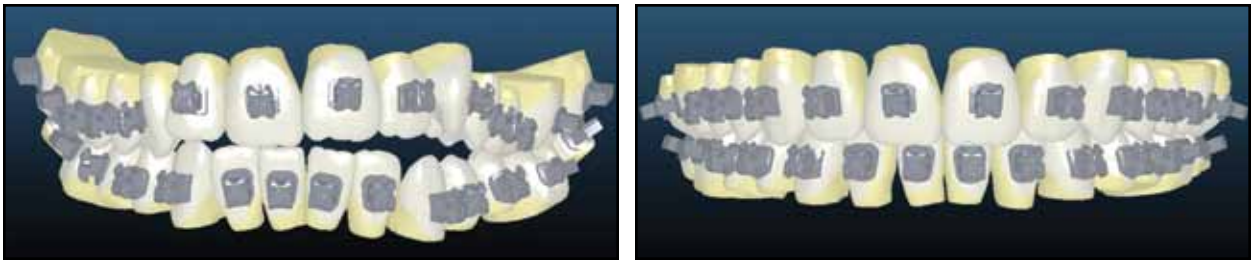


Fig. 8 Case 2. Insignia pre- and post-treatment virtual setups.

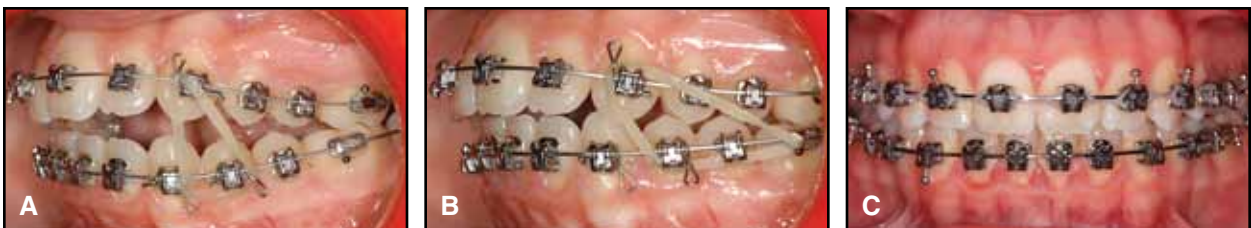

Fig. 9 Case 2. A. .014" × .025" Copper Ni-Ti archwires in place, with triangular elastic between upper left canine and lower left canine and first premolar. B. After four months of treatment, .018" × .025" Copper Ni-Ti archwires in place, with mandibular intermaxillary elastic attachment changed to first premolar and first molar to correct open bite and Class II malocclusion. C. Five months later, .019" × .025" stainless steel lower and TMA** upper archwires in place after closure of open bite and centering of midline.

Discussion

The Insignia system's patient-specific brackets, wires, and jigs permit precise definition of the final 3D tooth positions, taking into account both centric occlusal contacts and smile esthetics. By utilizing the views available in the Insignia Approver software, the clinician can compare the pre- and post-alignment virtual models with intra-oral, extraoral, and radiographic images. The setup can be refined by visualizing the effects of adjustments on such characteristics as labial protrusion, perioral strain on closure, lip thickness, gingival exposure and symmetry, and frontal tooth shapes and dimensions. The smile arc can be established while simultaneously observing photographs of the smile and anterior contact points to determine the need for adjustments of upper teeth, lower teeth, or both (Fig. 11). Posterior expansion can be calibrated while viewing the buccal corridors. Although cephalometric analysis is not a feature of the Approver software, tracings can be imported as image files, and measuring tools are available.

One current limitation of the system is the lack of information regarding dental roots, which

sometimes necessitates the addition of small corrective wire bends during the finishing phase, as in Case 1. This limitation will be resolved once DICOM[†] files from cone-beam CT scans are incorporated into the software.¹⁶

The Insignia system permits clinicians to collaborate on multidisciplinary treatment plans—defining, for example, the size of edentulous spaces to be rehabilitated or the movement of teeth to be treated prosthetically. The treating clinician's Insignia software is typically used for such interaction, whether in the office or remotely on a laptop computer, but it is possible for colleagues to install the Approver software on their own computers for visualization of shared Approver .cvs files. These proprietary setup files can be accessed with a user name and password and can thus be updated from anywhere in the world via an Internet connection.

Another benefit of the Insignia system is its ability to enhance communication with patients

**Trademark of Ormco, Orange, CA; www.ormco.com.

† NEMA, 1300 N. 17th St., Suite 1752, Rosslyn, VA 22209; www.dicom.nema.org.

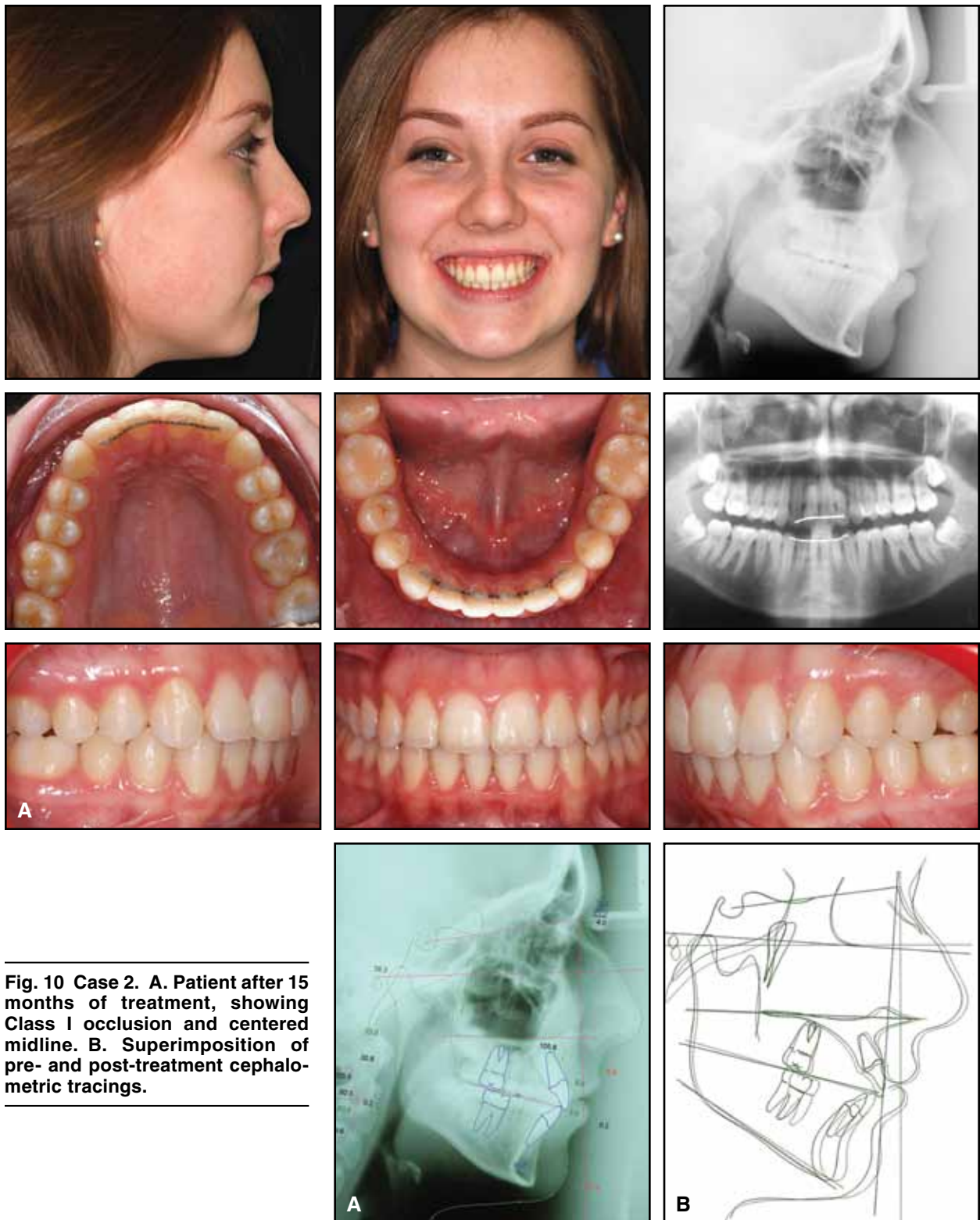


Fig. 10 Case 2. A. Patient after 15 months of treatment, showing Class I occlusion and centered midline. B. Superimposition of pre- and post-treatment cephalometric tracings.

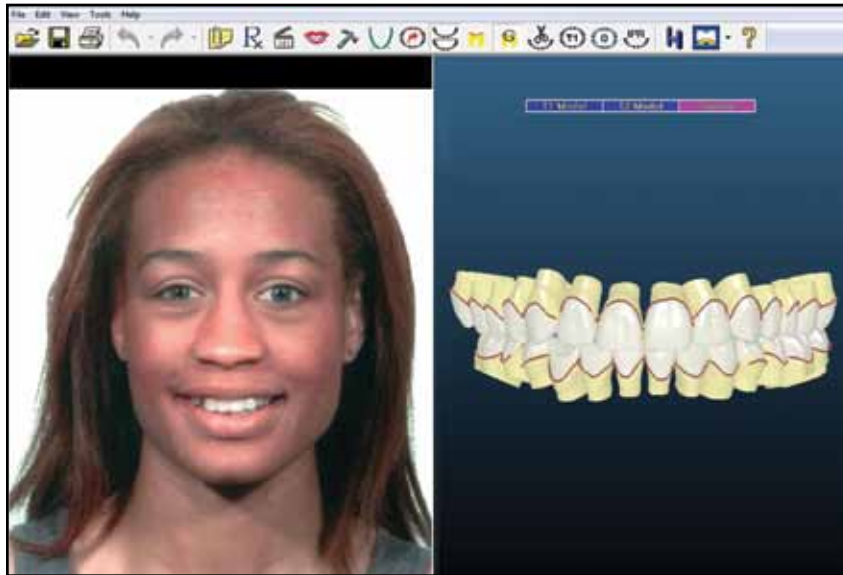


Fig. 11 Analysis of smile esthetics during clinician's modification to virtual setup.

during the treatment-planning process. Online or offline storage of all digital models, 3D simulations, photographs, and radiographs provides a useful and easily accessible patient-specific archive. Finally, the need for a large inventory of brackets, bands, and archwires to treat the wide variety of cases seen by most clinicians is practically eliminated with the use of patient-specific appliances.

Although the Approver software is intuitive and easy to use, any orthodontist who wants to treat patients with Insignia must take a short certification course covering the techniques required to produce precise PVS impressions, submit cases, access and manipulate virtual setups, indirectly bond patient-specific brackets using Insignia positioning jigs, and manage cases with the system. Certified clinicians are assigned user names and passwords for access to the Insignia website and their personal Insignia databases.

REFERENCES

- Keim, R.G.; Gottlieb, E.L.; Nelson, A.H.; and Vogels, D.S.: 2002 JCO Study of Orthodontic Diagnosis and Treatment Procedures, Part 1: Results and trends, *J. Clin. Orthod.* 36:553-568, 2002.
- Redmond, W.J.; Redmond, M.J.; and Redmond, W.R.: The OrthoCAD bracket placement solution, *Am. J. Orthod.* 125:645-646, 2004.
- Mayhew, M.J.: Computer-aided bracket placement for indirect bonding, *J. Clin. Orthod.* 39:653-660, 2005.
- Okunami, T.R.; Kusnoto, B.; BeGole, E.; Evans, C.A.; Sadowsky, C.; and Fadavi, S.: Assessing the American Board of Orthodontics objective grading system: Digital vs. plaster dental casts, *Am. J. Orthod.* 131:51-56, 2007.
- Costalos, P.A.; Sarraf, K.; Cangialosi, T.J.; and Efstratiadis, S.: Evaluation of the accuracy of digital model analysis for the American Board of Orthodontics objective grading system for dental casts, *Am. J. Orthod.* 128:624-629, 2005.
- Saxe, A.K.; Louie, L.J.; and Mah, J.: Efficiency and effectiveness of SureSmile, *World J. Orthod.* 11:16-22, 2010.
- Sachdeva, R.C.: SureSmile Technology in a patient-centered orthodontic practice, *J. Clin. Orthod.* 35:245-253, 2001.
- Mah, J. and Sachdeva, R.: Computer-assisted orthodontic treatment: The SureSmile process, *Am. J. Orthod.* 120:85-87, 2001.
- Sameshima, G.: Treatment time, *Orthod. Prod.*, June 2004, p. 22.
- Vassura, G.; Vassura, M.; Bazzacchi, A.; and Gracco, A.: A shift of force vector from arm to brain: 3D computer technology in orthodontic treatment management, *Int. Orthod.* 8:46-63, 2010.
- Scholz, R.P. and Sarver, D.M.: Interview with an Insignia doctor: David M. Sarver, *Am. J. Orthod.* 136:853-856, 2009.
- Mavreas, D. and Athanasiou, A.E.: Factors affecting the duration of orthodontic treatment: A systematic review, *Eur. J. Orthod.* 30:386-395, 2008.
- Fink, D.F. and Smith, R.J.: The duration of orthodontic treatment, *Am. J. Orthod.* 102:45-51, 1992.
- Vu, C.Q.; Roberts, W.E.; Hartsfield, J.K. Jr.; and Ofner, S.: Treatment complexity index for assessing the relationship of treatment duration and outcomes in a graduate orthodontic clinic, *Am. J. Orthod.* 133:9.e1-13, 2008.
- Andreiko, C.: 3D interactive treatment planning and patient-specific appliances, in *Lingual & Esthetic Orthodontics*, ed. R. Romano, Quintessence, Hanover Park, IL, 2011, pp. 157-166.
- Lin, E.: Class I with deep bite and crowding treated with lingual, i-Cat and SureSmile, *Orthotown*, December 2010, pp. 29-31.